

Case Report

A Case Report of Nonfibrinogenic Pneumoconiosis: Siderosis

Zeynep Dogrul,¹ Meral Turk,¹ Seher Kurtul,¹ Recep Savas²

¹Department of Public Health, Ege University Faculty of Medicine, Izmir, Turkey

²Department of Radiology, Ege University Faculty of Medicine, Izmir, Turkey

Abstract

Siderosis is a disease caused by the accumulation of nonfibrous iron oxide particles in the lung parenchyma. It can occur due to iron oxide exposure in workers employed in many industries, but is particularly evident in the mining, welding, and casting trades. The patient was a 42-year-old male who had been working in a casting factory for 19 years grinding ferrous metals. He presented with complaints of a cough and phlegm persisting for a year. He had a 19 pack/year smoking history. No pathological findings were observed in a respiratory system examination. We found no abnormality in a respiratory function test or a carbon monoxide diffusion test. A high resolution computed tomography image revealed bilateral, multiple, milimetric, ground-glass nodules. There was no growth in a sputum mycobacterium tuberculosis culture. Fiberoptic bronchoscopy indicated no pathological finding and bronchoalveolar lavage cytology was benign. Rheumatological markers were negative. Based on his occupational history and radiological findings, the diagnosis was siderosis. Siderosis has generally been considered a benign pneumoconiosis, since there is no fibrosis. There is no correlation between the clinical and radiological findings. Depending on the workplace environment, people who have been exposed to iron dust and fumes may also be exposed to other silicates, especially silica and asbestos. In this case, a mixed-type pneumoconiosis can occur. The present patient was also exposed to silica dust because of his work history in the metal grinding business, and he is in follow-up to monitor for siderosilicosis development.

Keywords: Pneumoconiosis, siderosis, occupational

Iron ore reserves have spread to almost all countries. Ukraine, Russia, Canada, China, Australia and Brazil are among the top countries with the largest iron ore reserves in the World. Japan, China and EU countries are the main importers. Our national reserves are concentrated in Divrigi, Bingöl, Kayseri regions. Iron ore mining is integrated with steel production in the world. Despite the fact that our country ranks first in steel production, 71% of steel production takes place in imported quartz furnaces and 29% is realized mainly in imported iron ore related integrated iron ore plants.^[1]

Exposure to occupational iron (CAS No: 7439-89-6) occurs as a result of inhalation of Fe₂O₃ particles.^[2] Mining, foundry, steel production, iron oxide production, abrasive stone production are cause of the exposure and pneumoconiosis which is called siderosis.^[3]

Case Report

Our present case, a 42 years old male patient, had been working in the cast iron factory for 19 years in the grinding of ferrous metals. He had complaints of cough and gray phlegm for a year. He had 19 packs/year smoking history.

Address for correspondence: Zeynep Dogrul, MD. Ege Universitesi Tıp Fakültesi Halk Sağlığı Anabilim Dalı, İş ve Meslek Hastalıkları Bilim Dalı, İzmir, Turkey

Phone: +90 535 626 08 45 **E-mail:** zeyrul@yahoo.com

Submitted Date: October 14, 2017 **Accepted Date:** November 20, 2017 **Available Online Date:** November 23, 2017

©Copyright 2017 by Eurasian Journal of Medicine and Investigation - Available online at www.ejmi.org



No pathological findings were found in the respiratory system examination. In his respiratory function test and carbonmonoxide diffusion test; FEV1/FVC: %80.87, FEV1: 2.94 L (%87), FVC: 3.63 L (%89), DLco: 23.00 ml/mmHg/min (%81), DLco/Va: 4.25 ml/mmHg/min/L (%91). In the HRCT (high resolution computed tomography) taken, millimetric nodular patterns were observed in both lungs. There was no growth in mycobacterium tuberculosis culture for bronchoalveolar lavage fluid. Cytology was negative. Serum ANA and anti-CCP values were negative in order to investigate rheumatological pathologies. Chest x-ray was interpreted as q/q 2/2 when assessed by ILO standards. The patient was interpreted as siderosis when evaluated by current study narrative and radiology. In this case, mixed type pneumoconiosis can occur. We were also exposed to silica dust because it works in the metal grinding business. The patient has been followed for siderosilicosis development.

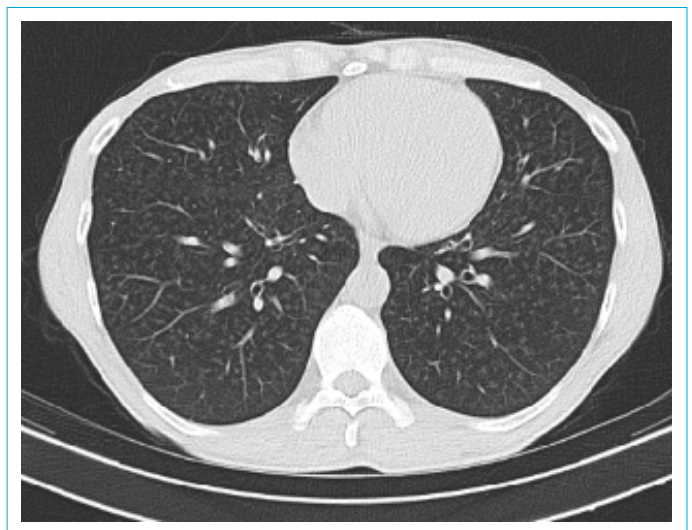
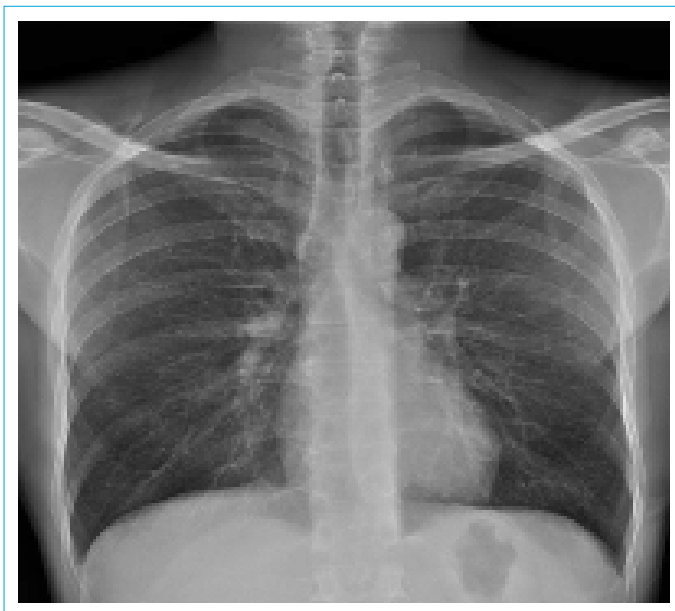Discussion

The metalworking industry produces machine parts and tools needed by different sectors. Basic metal processing techniques such as ore and scrap melting and refining, casting, hot or cold forging and pressing, welding and metal cutting, sintering and turning are applied in the sector. Grinding, polishing, sanding, surface treatment and various coating processes (electro-plating, galvanizing, heat treatment, anodizing, powder coating and so on) are made until the final product is obtained. Each of these processes has inherent risk sources and risks.^[1] Occupational diseases can be seen in almost every group in the metal work line in accordance with the occupational classification (physical factors, chemical agents, etc.) made according to the effect.

Aluminum oxide, silicon carbide, abrasive paper, garnet and flint are used in sanding and polishing tapes. Pulmonary diseases are a problem in workplaces where work without masks and ventilation is inadequate.^[3]

Siderosis is a disease caused by the accumulation of non-fibrous iron oxide particles in the lung parenchyma. It can be seen due to iron oxide exposure in workers who are working in many business lines, especially in mining, welding and casting industries. Since fibrosis is not an expected finding in the lung parenchyma, siderosis is considered benign pneumoconiosis.^[4] Patients are usually asymptomatic. However, in some cases there may be symptoms of chronic bronchitis. No pathologic findings may be detected in pulmonary function tests. In a study by Mao et al, which retrospectively evaluated 136 siderosis patients, lung function remained normal when all patients had mild symptoms such as cough, chest tightness and dyspnea.^[5] For diagnosis; bilateral diffuse nodules are detected on radiologic imaging. In the tissue samples taken from the lungs of the cases, iron oxide-filled macrophages are detected in the interstitium. There is no correlation between clinical and radiological findings, functional impairment is not an expected finding.^[6] Funahashi et al. observed moderate to pronounced fibrosis in 5 of 10 symptomatic welders. In these individuals, energy-dispersive X-ray analysis showed a large amount of iron in the lungs and no silica, eliminating coexisting silicosis as the etiology of the fibrosis.^[7]

However, people exposed to iron dust and fumes may also be exposed to silica and asbestos, as well as other silicates, depending on the work activity. In this situation, it is called mixed type pneumoconiosis, such as siderosilicosis. When it occurs, parenchymal fibrosis may accompany and the patient becomes symptomatic. Decrease in FEV1, FVC, DLco values is established. Radiological findings are similar to silicosis.



For this reason, the anamnesis of the cases with benign pneumoconiosis, like siderosis, should be detailed and these cases should be followed for development of mixed type pneumoconiosis.

Disclosures

Peer-review: Externally peer-reviewed.

Conflict of Interest: The authors have no conflicts of interest to declare.

Authorship contributions: Concept – Z.D.; Design – Z.D.; Supervision – S.K.; Materials – Z.D.; Data collection &/or processing – Z.D.; Analysis and/or interpretation – R.S.; Literature search – Z.D.; Writing – Z.D.; Critical review – M.T.

References

1. TMMOB Maden Mühendisleri Odası. Türkiye’de Demir Cevheri Madenciliği. Madencilik Bülteni Özel Sayı 2015. Available at: http://www.maden.org.tr/resimler/ekler/2a35cd5dbe7937a_ek.pdf. Accessed Nov 24, 2017.
2. Tozla Mücadele Yönetmeliği 2013. Available at: <http://www.resmigazete.gov.tr/eskiler/2013/11/20131105-9.htm>. Accessed Nov 24, 2017.
3. TC Çalışma ve Sosyal Güvenlik Bakanlığı. Meslek Hastalıkları ve İş İle İlgili Hastalıklar Tanı Rehberi. Available at: http://www.isgum.gov.tr/rsm/file/isgdoc/isgip/isgip_saglik_tani_rehberi.pdf. Accessed Nov 24, 2017.
4. Akkurt İ. Mesleki Solunum Hastalıkları. Ankara: Güneş Tıp Kitabevleri; 2014.
5. Mao L, Shi J, Chen Z, Zhang J. Welders' siderosis: a retrospective cohort study on welder's pneumoconiosis patients with small round opacities on chest radiograph. *Zhonghua Lao Dong Wei Sheng Zhi Ye Bing Za Zhi* 2014;32:823–7.
6. Kelleher P, Pacheco K, Newman LS. Inorganic dust pneumonias: the metal-related parenchymal disorders. *Environ Health Perspect* 2000;108 Suppl 4:685–96.
7. Funahashi A, Schlueter DP, Pintar K, Bemis EL, Siegesmund KA. Welders' pneumoconiosis: tissue elemental microanalysis by energy dispersive x ray analysis. *Br J Ind Med* 1988;45:14–8.